



ELSEVIER

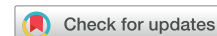Contents lists available at ScienceDirect

The Journal of Arthroplasty

journal homepage: www.arthroplastyjournal.org

Primary Arthroplasty

Comparing the Effect of Tourniquet vs Tourniquet-Less in Simultaneous Bilateral Total Knee Arthroplasties

Mohamed Shaher Hasanain, MD ^a, Dragos Apostu, MD ^{b,*}, Attaalh Alrefae, MD ^a, Samih Tarabichi, MD ^a^a Department of Orthopaedics, Burjeel Hospital for Advanced Surgery, Dubai, UAE^b Department of Orthopaedics and Traumatology, Iuliu Hatieganu University of Medicine and Pharmacy, Cluj-Napoca, Romania

ARTICLE INFO

Article history:

Received 27 December 2017

Received in revised form

1 February 2018

Accepted 3 February 2018

Available online 15 February 2018

Keywords:

bilateral total knee arthroplasty

tourniquet

blood loss

pain

range of motion

ABSTRACT

Background: Total knee arthroplasty (TKA) is a commonly performed procedure worldwide for the treatment of knee joint disease. Tourniquet is frequently used during the entire procedure to reduce blood loss and increase surgical comfort. On the other hand, tourniquet-related complications exist, and there are still controversies whether benefits outweigh the risks.

Methods: Patients undergoing simultaneous TKAs had one knee assigned to group A (use of tourniquet during the entire procedure) and the other knee assigned to group B (use of tourniquet only during cementation). Blood loss, intraoperative complications, implant alignment, soft tissue swelling, pain score, and range of motion were analyzed.

Results: Fifty-four patients undergoing 108 TKAs were included in the study. Total blood loss was almost 2 times higher in group B knees compared with group A. No difference was observed between groups in implant alignment, soft tissue swelling, pain, range of motion, or other early postoperative complications.

Conclusion: Tourniquet use in TKAs during the entire surgical procedure reduces total blood loss, without an increase in early postoperative complications.

© 2018 Elsevier Inc. All rights reserved.

Total knee arthroplasty (TKA) is a frequently performed orthopedic procedure worldwide, with a high rate of success in treating knee joint disease [1,2]. Complications related to the surgical procedure include blood loss, vascular lesions, nerve damage, extensor mechanism disruption, cardiovascular complications, pulmonary embolism, wound breakdown, knee stiffness, knee instability, persistent pain, and implant loosening [3].

Tourniquet is commonly used during TKA by more than 90% of orthopedic surgeons for preventing blood loss, increasing surgical comfort, better implant fixation, and decreasing surgical time [4–7]. The tourniquet use has potential risks, including thigh pain, soft tissue damage, nerve injury, rhabdomyolysis, vascular injury, subcutaneous fat necrosis, infections, and deep vein thrombosis

(DVT) [2,5,8,9]. There are still controversies in the literature on whether or not benefits exceed the risks [5].

There is no study in the current literature to compare the effects of tourniquet used during the entire procedure with tourniquet use during implant cementing in simultaneous bilateral TKAs [10–14]. The purpose of the study is to determine the best technique of using a tourniquet in TKAs, by analyzing their benefits and risks.

Patients and Methods

The research received the Ethics Commission Approval and consisted in a randomized controlled study on patients undergoing simultaneous bilateral TKA at our institution, from August 2013 until October 2014. Exclusion criteria included coagulopathy (bleeding time >9 minutes, partial thromboplastin time <60 seconds and >70 seconds, activated partial thromboplastin time <30 seconds and >40 seconds, and prothrombin time <11 seconds and >14 seconds), low hemoglobin (<12 mg/dL), ischemic heart disease (positive functional or stress tests), uncontrolled hypertension (systolic blood pressure ≥140 mm Hg or an average diastolic blood pressure of ≥90 mm Hg), peripheral artery disease (Fontaine stages II, III, and IV),

One or more of the authors of this paper have disclosed potential or pertinent conflicts of interest, which may include receipt of payment, either direct or indirect, institutional support, or association with an entity in the biomedical field which may be perceived to have potential conflict of interest with this work. For full disclosure statements refer to <https://doi.org/10.1016/j.arth.2018.02.013>.

* Reprint requests: Dragos Apostu, MD, 37 Buna Ziua Street, E1B/2/50, Cluj-Napoca 400495, Romania.

<https://doi.org/10.1016/j.arth.2018.02.013>

0883-5403/© 2018 Elsevier Inc. All rights reserved.

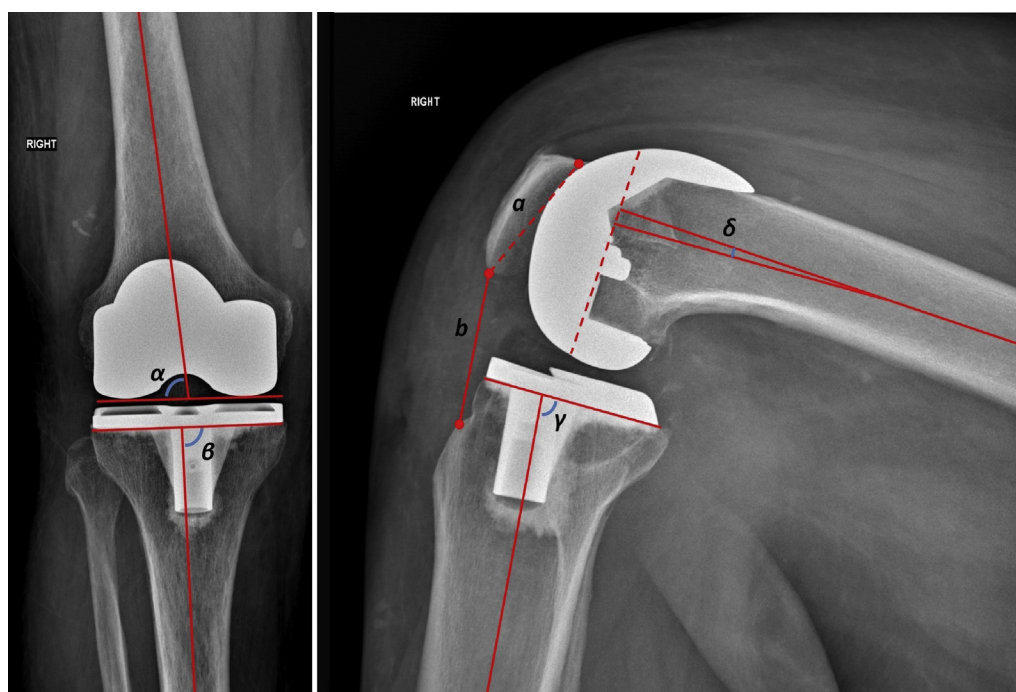


Fig. 1. Postoperative radiological measurements on knee anteroposterior (AP) view (left x-ray) and lateral view (right x-ray).

and chronic venous disorders (Clinical Etiologic Anatomic Pathophysiologic stages 2–6).

Collected preoperative data included patient's gender, age, and medical history. The left and right knees were randomized blindly (using the system of sealed envelopes) into 2 groups: group A—with the use of a tourniquet during the entire surgical procedure; group B—with the use of a tourniquet only during implant cementing.

Surgical Protocol

The surgeries were performed by the same surgeon and anesthesiologist. All patients had perioperative management including 1.5 grams of intravenous cefuroxime and 1 gram of intravenous tranexamic acid at the induction of spinal anesthesia. The surgeon and the anesthesiologist were unaware of the allocation within groups until the sealed envelopes were opened after the induction of anesthesia. All the surgeries were first performed on the right knees, regardless of the allocation within groups, followed by the left knees. In group A, the leg was then exsanguinated using elevation and Esmarch bandage. Consequently, the tourniquet was inflated at a value of 100–150 mm Hg above the systolic blood pressure, up to a maximum of 350 mm Hg. In group B knees, the tourniquet was installed during the preparation and kept deflated. An Automatic Tourniquet System 3000 from Zimmer with a 42-inch cuff was used during the study.

The skin incision and subvastus approach were performed in knee extension, whereas the rest of the surgery was performed in 90 degrees of knee flexion. Before implant cementing in group B knees, we inflated the tourniquet. Pulse lavage was used, and bone beds were prepared. Moreover, the drill hole in the distal femur was filled with autogenous bone graft plug. When the bone beds were dry, we applied Palacos cement with gentamicin for implant fixation. Patella was not resurfaced in any of the groups. All the implants used during this study were cemented posterior stabilized TKAs from Zimmer. Ten minutes after implants cementing, the tourniquet was deflated in group B knees.

Difficulty in visualizing anatomical landmarks including tibial tuberosity, Whiteside's line, transepicondylar axis, medial and

lateral epicondyles because of increased intraoperative hemorrhage was recorded as follows: good visualization, acceptable visualization, and poor visualization.

One suction drain was inserted before closure and a 50 mL cocktail including 2% lidocaine and 750 mg of cefuroxime was injected into the knee joint space for pain management and antibioprophyllaxis. After sterile dressing application, the tourniquet was deflated in group A knees. A compressive dressing was applied.

Postoperative Protocol

Patients, physiotherapists, and nurses were unaware of the randomization.

Postoperative drug administration included cefuroxime for 72 hours postoperatively at a dose of 4.5 grams/d and 5 weeks of Dabigatran 220 mg or Xarelto 10 mg daily, started 6 hours postoperatively. The drains were removed 24 hours after surgery.

All the patients received the same physiotherapy protocol starting on the first postoperative day, including muscle strength training, passive range of motion (ROM) exercises, active ROM training, and walking training, all supervised by the same physiotherapy team. The patients were followed up for 3 months after the surgical procedure.

Collected data included postoperative blood loss, pain score, ROM, thigh circumference, and radiological measurements of femoral and tibial implants' positioning. Other complications including DVT, infections, and delayed wound healing were recorded. Ultrasonography for diagnosis of DVT was performed only in the presence of clinical symptoms.

Table 1
Descriptive Statistics of Age and BMI Within Patients.

	Number	Minimum	Maximum	Mean	SD
Age	54	49	77	62.93	7.483
BMI	54	25	44	32.41	4.882

BMI, body mass index; SD, standard deviation.

Table 2
Intraoperative Visualization of Anatomical Landmarks.

	Poor Visualization	Acceptable Visualization	Good Visualization
Group A (tourniquet)	4 (7.4%)	14 (25.9%)	36 (66.6%)
Group B (tourniquet-less)	27 (50%)	19 (35.1%)	9 (16.6%)

Calculations and Measurements

Intraoperative blood loss was calculated as the volume of liquid in the suction bottle minus the volume of irrigation fluid used throughout the surgery. The increase in surgical gauze weight used was also added to the total blood loss. Postoperative blood loss was calculated using the graduated cylinders within the suction drainage system. All the blood loss calculations were performed by the same surgeon.

Visual analog scale was assessed daily by the same surgeon during the first 10 days postoperatively as inpatient, as well as at 3, 5, 8, and 12 weeks postoperatively as outpatient. Thigh pain was not distinguished from wound pain.

The time needed to achieve straight-leg raise was recorded. Knee ROM was assessed daily using a goniometer, at the edge of the bed, by the same physiotherapist, during the first 10 days postoperatively, as well as at 3, 5, 8, and 12 weeks after surgery. The goniometer was aligned using lateral malleolus, lateral femoral condyle, and the greater trochanter as bony landmarks. Every measurement was performed within the physiotherapy department in our institution.

Thigh circumference was measured daily as inpatient by the same surgeon for the first 7 days at the site of tourniquet placement to assess soft tissue swelling.

Bilateral anteroposterior and lateral x-rays were performed in the first postoperative week. The following parameters were measured: anatomic lateral distal femoral angle (α) and medial proximal tibial angle (β) on the weight-bearing anteroposterior view; tibial slope (γ), femoral component flexion/extension angle (δ), and Insall-Salvati ratio (b/a) on the lateral view (Fig. 1). The measurements were performed twice by the same examiner and the average had been taken into account. If the difference between measurements was more than 2°, both measurements were repeated. The technique of performing the measurements was described by Sarmah et al [15], and the following were the reference values used in the study: anatomic lateral distal femoral angle [80°-86°], medial proximal tibial angle [90° ± 3], tibial slope [85°-90°], femoral component flexion/extension angle [0° ± 3], and Insall-Salvati ratio [0.8-1.2] [16].

Statistics

For statistical analysis, we calculated means, standard deviations, frequencies, and percentages. Normal distribution was checked using Shapiro-Wilk test. Paired Student *t* test was performed and *P* values <.05 were considered to be statistically significant. Statistical calculations were performed using Microsoft

Table 3
Descriptive Statistics of Radiological Measurements of Component Positioning.

	Group A (n = 39)		Group B (n = 39)		Student <i>t</i> Test
	Average	Outliers	Average	Outliers	<i>P</i> Value
Anatomic lateral distal femoral angle	85.31° [79.81°-89.58°]	13	84.98° [78.17°-88.06°]	15	.49
Medial proximal tibial angle	89.11° [84.16°-92.82°]	5	89.21° [84.76°-92.85°]	6	.83
Tibial slope	86.69° [79.78°-93.45°]	21	87.06° [78.74°-96.04°]	26	.69
Femoral component flexion/extension angle	2.56° [0.12°-8.64°]	14	2.91° [0.1°-9.04°]	15	.49
Insall-Salvati ratio	0.93° [0.67°-1.37°]	9	0.90° [0.70°-1.28°]	9	.32

Windows SPSS, version 15.0 (Statistical Package for the Social Science; SPSS Inc, Chicago, IL).

Results

Fifty-four patients undergoing simultaneous bilateral TKA were included in the study. Female represented 63% (n = 34) of the patients. In group A, there were 37 right knees and 17 left knees, whereas group B was represented by 17 right knees and 37 left knees. Descriptive statistics regarding age and body mass index are shown in Table 1.

Most patients included in the study (n = 52, 96.3%) had the diagnostic of knee osteoarthritis, whereas the rest of the patients (n = 2, 3.7%) were diagnosed with rheumatoid arthritis of the knee.

Surgical Complications

More intraoperative visualization difficulties of anatomical landmarks, due to excessive bleeding, were encountered in group B knees (Table 2). As a result, subjectively more electrocautery, a more frequent pulse lavage, suction, and dry gauzes were applied to maintain a relatively bloodless field during implant cementing. Despite the use of these methods, blood was still present in bony trabeculae before cementation in case of tourniquet-less knees.

In group B, we encountered 2 cases of intraoperative partial injury to the patellar tendon, without the need of repair or augmentation, and 1 case of superficial wound infection, which was successfully treated. No such complications were observed in group A. On the other hand, we found no vascular injuries, nerve lesions, cardiovascular events, or clinical symptoms of DVT in any of the groups.

Blood Loss

The intraoperative blood loss in group A was 91.35 ± 57.32 mL, compared with 478.53 ± 253.65 mL in group B knees. The difference was statistically significant (*P* < .0001). The mean postoperative blood loss was 361.76 ± 222 mL in the group A, lower compared with group B (mean of 408.28 ± 192.41 mL), but the difference was not statistically significant. The overall blood loss was almost double in group B knees (453.11 ± 246.35 mL) compared with group A (886.81 ± 364.11 mL).

Radiological Measurements

Seventy-eight anteroposterior and lateral view x-rays were analyzed (39 in group A and 39 in group B). No statistically significant differences (*P* < .05) were found between groups regarding anatomic lateral distal femoral angle, medial proximal tibial angle, tibial slope, femoral component flexion/extension angle, and Insall-Salvati ratio (Table 3). Nevertheless, there was an increased number of outliers in group B (tourniquet-less) compared with group A knees of almost all of the parameters (Table 3).

Table 4
Mean Postoperative Pain Score After Total Knee Arthroplasty in Groups A and B.

	Day 1	Day 2	Day 3	Day 4	Day 5	Day 6	Day 7	Day 8	Day 9	Day 10	W3	W5	W8	W12
Group A (tourniquet)	4	3.51	3.22	3	2.59	2.48	2.29	2.14	2.09	1.92	3.70	2.62	2.09	1.96
Group B (tourniquet-less)	3.88	3.37	3.33	2.88	2.48	2.48	2.48	2.14	2.05	1.92	2.70	2.44	2.03	1.77

W3, visual analog scale at 3 weeks postoperatively; W5, visual analog scale at 5 weeks postoperatively; W8, visual analog scale at 8 weeks postoperatively; W12, visual analog scale at 12 weeks postoperatively.

Pain

Postoperative pain was slightly more in the tourniquet group (Table 4), but the results were not statistically significant. The only significant difference ($P < .001$) was found at week 3 postoperatively, when group A had a higher mean pain score (3.7 ± 1.75) compared with the group B (2.7 ± 1.12) (Table 4).

Soft Tissue Swelling

Postoperative thigh circumference was higher in group B knees (tourniquet used only during cementation), but a statistically significant difference was found only at 5 days postoperatively ($P = .024$), with a mean of 57.85 ± 6.73 cm in group A and 58.59 ± 6.86 cm in group B (Fig. 2). The thigh diameter equalized in the sixth postoperative day.

Range of Motion

The mean postoperative flexion in day 1 was the same in both groups (87.6°) (Fig. 3). All the patients could fully extend the knees and perform straight-leg raise in the first postoperative day. At 10 days postoperatively, patients could flex the knees to an average of $110.67^\circ \pm 17.3^\circ$ for group A and $109.67^\circ \pm 15.7^\circ$ for group B (Fig. 3). Both groups reached a mean of around 138 degrees of flexion at 8 weeks postoperatively (138.06° for group A and 138.15° for group B; Fig. 3). The only statistically significant difference was found at 5 weeks postoperatively ($P = .02$), when group A had a lower ROM average compared with group B (123.89° vs 126.85°) (Fig. 3).

A weak correlation between ROM and pain ($r = 0.30$) has been shown. There was no correlation neither between ROM and thigh diameter ($r = 0.21$), nor between thigh diameter and pain ($r = 0.10$).

Discussions

To our knowledge, the present study has the highest number of patients and parameters than any other research that compares the tourniquet effect in simultaneous TKA [13,14]. Moreover, it is the first study to compare tourniquet use during the entire surgical procedure with its use only during cementing, in simultaneous TKAs. Studies on simultaneous TKAs, compared with those on unilateral knee arthroplasties [10–12], eliminate the differences between patients in surgical technique, pain thresholds, hemostasis, rehabilitation protocols, comorbidities, and pain management, which can affect results.

An impaired visualization of anatomical structures during surgery caused by hemorrhage can lead to iatrogenic injuries and implant malalignment. Both cases of partial injuries of the patellar tendon were found in group B knees, suggesting a higher risk of iatrogenic injuries in case of tourniquet use only during cementation. Although these intraoperative complications in our study did not require repair, it is important to state that a high-volume surgeon performed all the procedures. Therefore, a bloody surgical field could have a greater effect on a low-volume surgeon, leading to more frequent and more severe intraoperative complications [16,17].

Regarding implant alignment, our postoperative radiological findings showed an increased number of outliers in several parameters affecting group B knees, but did not suggest a statistically significant malpositioning of the components. A limit of our study is that it did not quantify components' mechanical axis alignment and rotation. For mechanical axis alignment measurements, long leg x-rays are needed, as for components' rotation, these can be calculated using computed tomography. Both these methods are not routinely performed in our institution after TKAs. To our knowledge, this is the first study to compare implant alignment in tourniquet vs tourniquet-less TKAs.

The blood present in bone trabeculae before cementation in group B knees, despite a higher use of electrocautery, pulse-lavage, suction, and dry gauzes, does not seem to affect implant survival, but long-term studies are required [18,19]. A limitation of the present study is that objective methods to quantify lavage fluid, number of gauzes used, or time of electrocautery use during the surgeries were not used.

The single case of superficial wound infection, occurring in group A, could be explained by a possible wound hypoxia postoperatively, produced by the tourniquet [20]. The absence of DVT in our study is contrary to other studies on simultaneous bilateral TKA [21]. This could be explained by excluding patients with chronic venous disorders (Clinical Etiologic Anatomic Pathophysiologic 2-6) and by not performing ultrasonography systemically. Nerve lesions were not detected, most likely due to an appropriate use of tourniquet pressure [22,23].

The difference between group A and B in terms of blood loss is according to other studies in the literature [6,7,24,25]. On the contrary, there are studies which showed a higher blood loss when a tourniquet was used [26,27]. According to Mraovic et al [27], limiting blood loss is important in lowering blood transfusions, decreasing surgical site infections and costs.

The similar pain scores between groups in our study is against previous studies on simultaneous bilateral knees, in which lower pain levels were found in TKAs without applying a tourniquet [14,21]. The difference can be explained by the fact that unlike our study, the previous articles did not have a group of tourniquet use only during cementation. During our study, we used a tourniquet pressure of 100–150 mm Hg above the systolic blood pressure, which is recommended by Worland et al [13] for a reduced

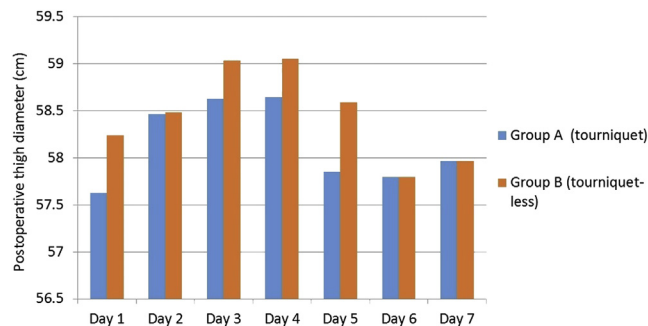


Fig. 2. Mean postoperative thigh circumference in groups A and B knees.

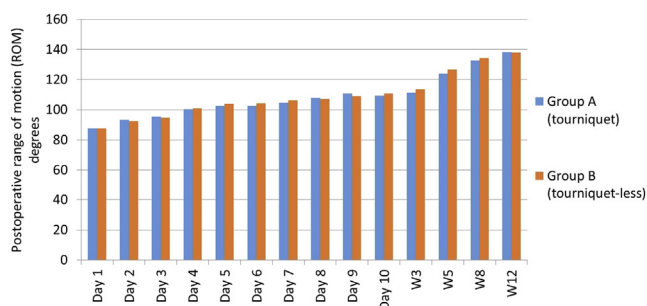


Fig. 3. Mean degrees of flexion after total knee arthroplasties in groups A and B throughout rehabilitation period. W3, range of motion at 3 weeks postoperatively; W5, range of motion at 5 weeks postoperatively; W8, range of motion at 8 weeks postoperatively; W12, range of motion at 12 weeks postoperatively.

postoperative pain. Other studies used different tourniquet pressures, which might influence the result [28–32]. The low pain scores in the early postoperative days might indicate a good pain management. The difference in pain was observed only at the third postoperative week because during hospitalization we have been using an aggressive protocol for pain management, and some of those narcotics were not able to be used as outpatient.

Our study did not assess the knee muscle strength and functional outcome such as Western Ontario and McMasters Universities Osteoarthritis Index Score, Lysholm Knee Score, and International Knee Documentation Committee Knee Form. These scores could point out a relation between the technique of tourniquet use and activity, symptoms, as well as knee function.

The soft tissue swelling, higher in group B knees, could be explained by the more severe surgical trauma and more postoperative inflammation in the knees without tourniquet. Tai et al [31] determined C-reactive protein and creatinine phosphokinase and concluded that the use of a tourniquet during TKAs was effective in avoiding excessive postoperative inflammation and muscle damage. In our study, the soft tissue swelling has a peak at the fourth postoperative day, according to erythrocyte sedimentation rate and C-reactive protein levels [32]. High swelling does not seem to affect ROM and pain values according to our results.

The similar results in ROM and functional outcome were according to other studies in the literature performed both on simultaneous bilateral [21] and unilateral TKAs [2,33], both groups achieving an excellent outcome at 3 months postoperatively. The straight-leg raise performed on the first postoperative day by all patients is against a previous study on simultaneous bilateral TKA, where patients first performed straight-leg rise at an average of 3 days postoperatively [21]. This difference could be explained by a different rehabilitation protocol between the 2 institutions.

Throughout our study, potential risk related to using a tourniquet such as vascular injuries, nerve lesions, cardiovascular events, or DVT were not encountered. Parvizi and Diaz-Ledezma [34] stated that most complications mentioned previously are likely to be multifactorial, therefore a conclusive cause-effect relationship cannot be established.

This randomized controlled study had some limitations. Although we showed that intraoperative blood loss was significantly less in the tourniquet group, Sehat et al [35] showed that there is an uncalculated blood loss quantity that could not be calculated in our study. We did not distinguish between thigh and knee pain during our assessment, a drawback which could explain the difference between our result and other studies on simultaneous TKAs [14]. The surgeon performing all the TKAs is a high-volume surgeon, better prepared to deal an impaired visualization of anatomical landmarks because of a bloody surgical field. On the

other hand, a low-volume surgeon might have an increased rate of intraoperative complications compared with our study's results.

Conclusion

The use of a tourniquet in TKAs during the entire procedure is safe, results in lower blood loss and better visualization of anatomical landmarks compared with the use of a tourniquet only during cementing. The study showed no significant differences between groups in pain, soft tissue swelling, implant alignment, ROM, or other early postoperative complications.

Acknowledgments

This research did not receive any specific grant from funding agencies in the public, commercial, or not-for-profit sectors.

References

- [1] Maradit Kremers H, Larson DR, Crowson CS, Kremers WK, Washington RE, Steiner CA, et al. Prevalence of total hip and knee replacement in the United States. *J Bone Joint Surg Am* 2015;97:1386–97.
- [2] Zhang W, Li N, Chen S, Tan Y, Al-Aidaros M, Chen L. The effects of a tourniquet used in total knee arthroplasty: a meta-analysis. *J Orthop Surg Res* 2014;9:13.
- [3] Healy WL, Della Valle CJ, Iorio R, Berend KR, Cushner FD, Dalury DF, et al. Complications of total knee arthroplasty: standardized list and definitions of the Knee Society. *Clin Orthop Relat Res* 2013;471:215–20.
- [4] Ahmed I, Fraser L, Sprowson A, Wall P. Tourniquets for the use of total knee arthroplasty: are patients aware of the risks? *Ann Orthopedics Rheumatol* 2016;4:1071.
- [5] Sharma JP, Salhotra R. Tourniquets in orthopedic surgery. *Indian J Orthop* 2012;45:377–83.
- [6] Vandebussche E, Duranthon LD, Couturier M, Pidhorz L, Augereau B. The effect of tourniquet use in total knee arthroplasty. *Int Orthop* 2002;26:306–9.
- [7] Harvey EJ, Leclerc J, Brooks CE, Burke DL. Effect of tourniquet use on blood loss and incidence of deep vein thrombosis in total knee arthroplasty. *J Arthroplasty* 1997;12:291–6.
- [8] Irvine GB, Chan RN. Arterial calcification and tourniquets: letter. *Lancet* 1986;2:1217.
- [9] Tamvakopoulos GS, Toms AP, Glasgow M. Subcutaneous thigh fat necrosis as a result of tourniquet control during total knee arthroplasty. *Ann R Coll Surg Engl* 2005;87:W11–3.
- [10] Tarwala R, Dorr LD, Gilbert PK, Wan Z, Long WT. Tourniquet use during cementation only during total knee arthroplasty: a randomized trial. *Clin Orthop Relat Res* 2014;472:169–74.
- [11] Fan Y, Jin J, Sun Z, Lin J, Weng X, Qiu G. The limited use of a tourniquet during total knee arthroplasty: a randomized controlled trial. *Knee* 2014;21:1263–8.
- [12] Kvederas G, Porvaneckas N, Andrijauskas A, Svensen CH, Ivaskivicius J, Mazunaitis J, et al. A randomized double-blind clinical trial of tourniquet application strategies for total knee arthroplasty. *Knee Surg Sports Traumatol Arthrosc* 2013;21:2790–9.
- [13] Worland RL, Arredondo J, Angles F, Lopez-Jimenez F, Jessup DE. Thigh pain following tourniquet application in simultaneous bilateral total knee replacement arthroplasty. *J Arthroplasty* 1997;12:848–52.
- [14] Kumar N, Yadav C, Kumar A, Vaithlingam A, Yadav S. Evaluation of pain in bilateral total knee replacement with and without tourniquet: a prospective randomized control trial. *J Clin Orthop Trauma* 2015;6:85–8.
- [15] Sarmah SS, Patel S, Hossain FS, Haddad FS. The radiological assessment of total and unicompartmental knee replacements. *J Bone Joint Surg* 2012;94-B:1321–9.
- [16] Math KR, Zaidi SF, Petchprapa C, Harwin SF. Imaging of total knee arthroplasty. *Semin Musculoskelet Radiol* 2006;10:47–63.
- [17] Ravi B, Jenkinson R, Austin PC, Croxford R, Wasserstein D, Escott B, et al. Relation between surgeon volume and risk of complications after total hip arthroplasty: propensity score matched cohort study. *BMJ* 2014;348:g3284.
- [18] Molt M, Harsten A, Toksvig-Larsen S. The effect of tourniquet use on fixation quality in cemented total knee arthroplasty: a prospective randomized clinical controlled RSA trial. *The Knee* 2014;21:396–401.
- [19] Ledin H, Aspenberg P, Good L. Tourniquet use in total knee replacement does not improve fixation, but appears to reduce final range of motion. *Acta Orthop* 2012;83:499–503.
- [20] Clarke MT, Longstaff L, Edwards D, Rushton N. Tourniquet-induced wound hypoxia after total knee replacement. *J Bone Joint Surg* 2001;83:40–4.
- [21] Liu PL, Li DQ, Zhang YK, Lu QS, Ma L, Bao XZ, Zhang M. Effects of Unilateral Tourniquet Used in Patients Undergoing Simultaneous Bilateral Total Knee Arthroplasty. *Orthop Surg* 2017;9:180–5.
- [22] Olivecrona C, Blomfeldt R, Ponzer S, Stanford BR, Nilsson BY. Tourniquet cuff pressure and nerve injury in knee arthroplasty in a bloodless field. A neurophysiological study. *Acta Orthop* 2013;84:159–64.

- [23] Tai TW, Lin CJ, Jou IM, Chang CW, Lai KA, Yang CY. Tourniquet use in total knee arthroplasty: a metaanalysis. *Knee Surg Sports Traumatol Arthrosc* 2011;19:1121–30.
- [24] Fukuda A, Hasegawa M, Kato K, Shi D, Sudo A, Uchida A. Effect of tourniquet application on deep vein thrombosis after total knee arthroplasty. *Arch Orthop Trauma Surg* 2007;127:671–5.
- [25] Li B, Wen Y, Wu H, Qian Q, Lin X, Zhao H. The effect of tourniquet use on hidden blood loss in total knee arthroplasty. *Int Orthop* 2009;33:1263–8.
- [26] Tetro AM, Rudan JF. The effects of a pneumatic tourniquet on blood loss in total knee arthroplasty. *Can J Surg* 2001;44:33–8.
- [27] Mraovic B, Suh D, Jacovides C, Parvizi J. Perioperative hyperglycemia and postoperative infection after lower limb arthroplasty. *J Diabetes Sci Technol* 2011;5:412–8.
- [28] Wakankar HM, Nicholl JE, Koka R, D'Arcy JC. The tourniquet in total knee arthroplasty. A prospective, randomised study. *J Bone Joint Surg Br* 1999;81:30–3.
- [29] Burkart BC, Bourne RB, Rorabeck CH, Kirk PG, Nott L. The efficacy of tourniquet release in blood conservation after total knee arthroplasty. *Clin Orthop* 1994;299:147–52.
- [30] Stringer MD, Steadman CA, Hedges AR, Thomas EM, Morley TR, Kakkar VV. Deep vein thrombosis after elective knee surgery. An incidence study in 312 patients. *J Bone Joint Surg Br* 1989;71:492–7.
- [31] Tai TW, Chang CW, Lai KA, Lin CJ, Yang CY. Effects of tourniquet use on blood loss and soft-tissue damage in total knee arthroplasty: a randomized controlled trial. *J Bone Joint Surg Am* 2012;94-A:2209–15.
- [32] Nazem K, Motifard M, Yousefian M. Variations in ESR and CRP in total knee arthroplasty and total hip arthroplasty in Iranian patients from 2009 to 2011. *Adv Biomed Res* 2016;5:148.
- [33] Liu D, Graham D, Gillies K, Gillies RM. Effects of tourniquet use on quadriceps function and pain in total knee arthroplasty. *Knee Surg Relat Res* 2014;26:207–13.
- [34] Parvizi J, Diaz-Ledezma C. Total knee replacement with the use of a tourniquet: more pros than cons. *Bone Joint J* 2013;95-B(11 Suppl A):133–4.
- [35] Sehat KR, Evans RL, Newman JH. Hidden blood loss following hip and knee arthroplasty. Correct management of blood loss should take hidden loss into account. *J Bone Joint Surg Br* 2004;86:561–5.